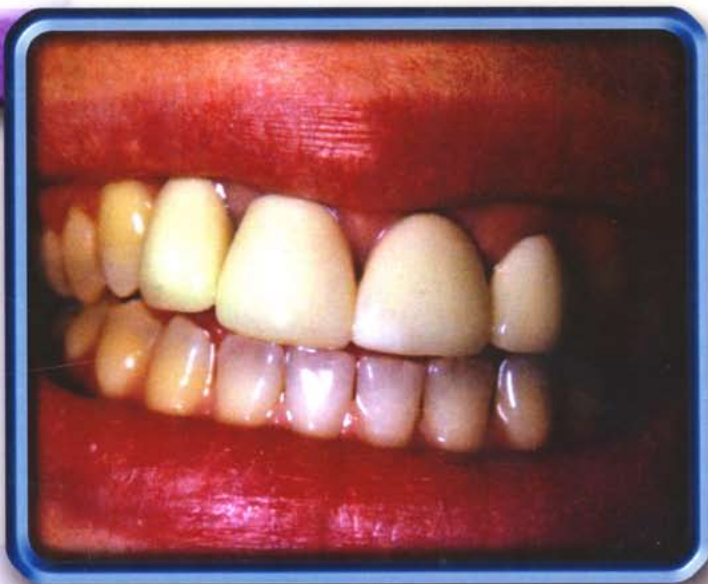

## CONCERNS

Four front teeth, color is flat, not life like, refrigerator door appearance, too bulky, poor shape, incorrect length/width. All teeth appear to be pointed in different directions, edges of teeth not even, not symmetrical, gum line is uneven, black/grey line showing at gumline indicating poor materials selection.

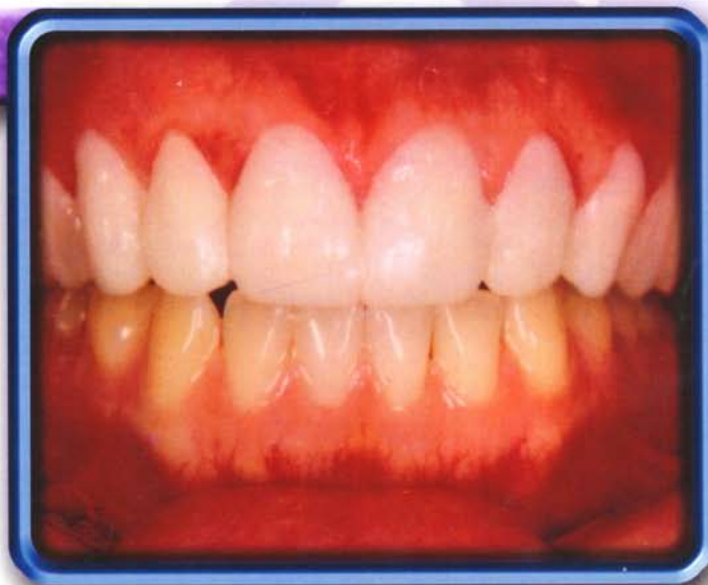Worst point; the patient was told this was the best that could be done for her!



## SOLUTION

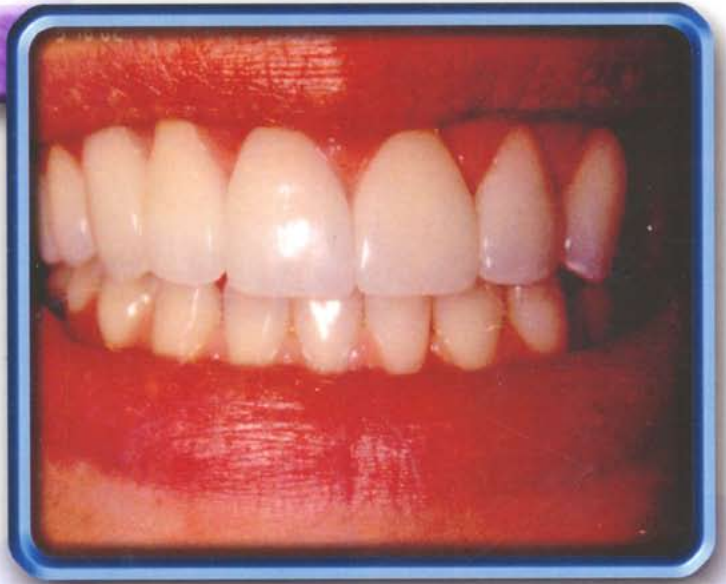Instead of treating four teeth, smile line was expanded using ten teeth, proper tooth length/width/edge design appropriate to the patient's face was placed. These are "Temporaries" the patient will wear for about 2 1/2 to 3 weeks.

This will give the patient an opportunity to test drive her new smile.



## RESULTS

Final restorations in place three weeks later. Notice symmetry, natural appearance of treated teeth, teeth are correct length, width, angulation, no more black/grey lines. Gums look healthy.



## RESULTS

Nice smile!



## CONCERNS

Loose, crooked, dark yellow/brown color. This patient was told she would be losing all her teeth. Notice the patient's expression.



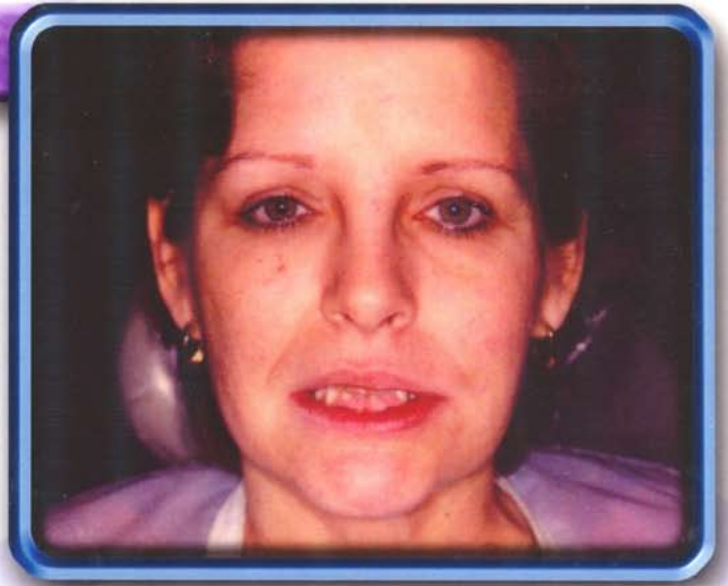## SOLUTION

Conventional as well as advanced laser treatment techniques to stabilize teeth, placement of 14 ceramic units. Notice how engaged the patient's expression is.



## CONCERNS

Broken down teeth, worn, decayed and out of position. Notice the patient's eyes, lines around her mouth and face.



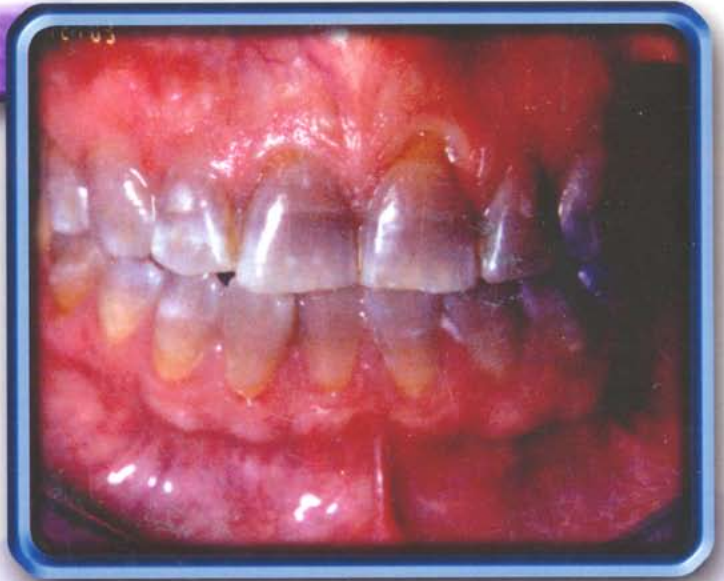## SOLUTION

Because the teeth hold-up the lower third of our face, it's important to have the proper tooth length. When the teeth are the proper length/width the face is supported, the lips filled out and some wrinkles will go away or become less noticeable. Total treatment in two weeks.



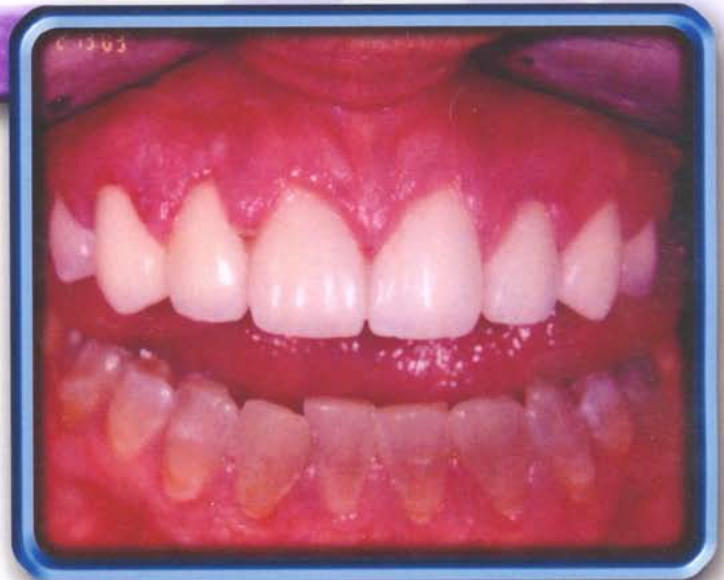## CONCERNS

Dark Tetracycline stained teeth, worn teeth, limited budget.



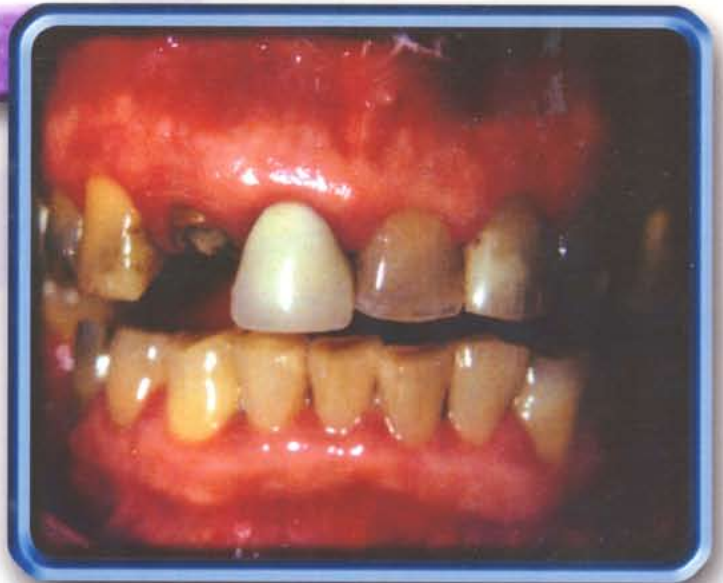## SOLUTION

The patient chose to treat eight teeth, which was most of her smile, she has the choice to complete more teeth later. The patient chose a very bright white color ceramic, this was a life changing treatment for this patient.



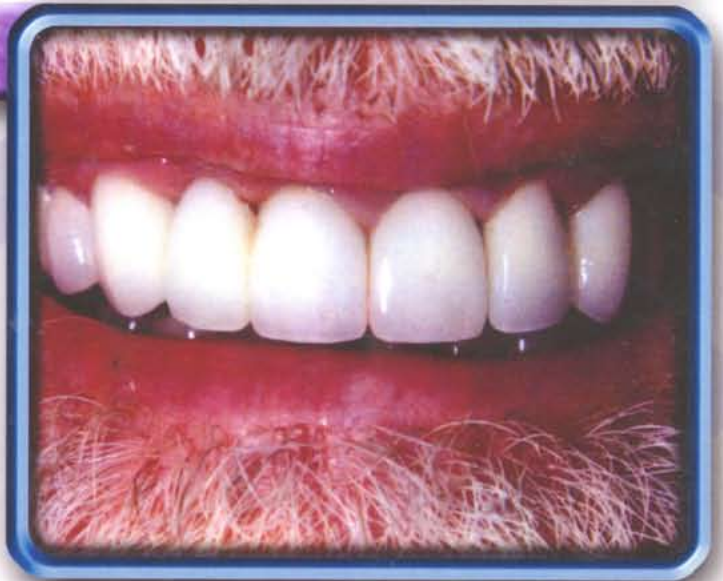## CONCERNS

Broken, decayed and missing teeth.




## SOLUTION

Two weeks later, patient had ten teeth treated to proper length/width using ceramic restorations.

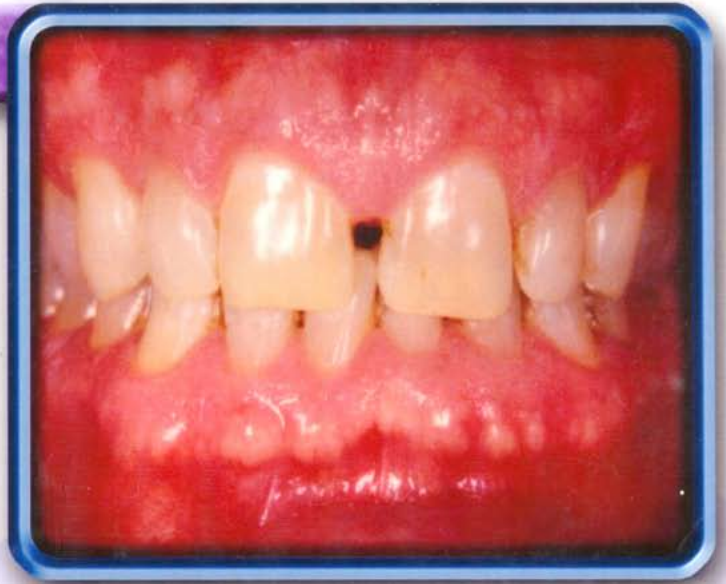

Color was selected to compliment the patients facial hair!



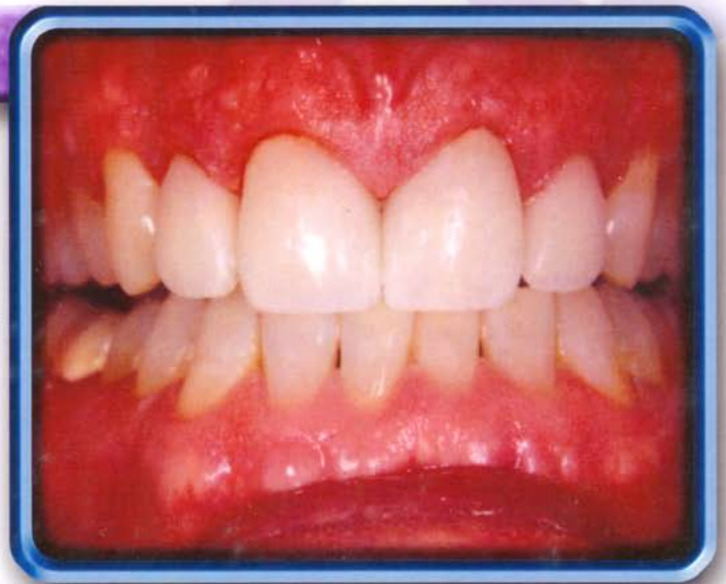## CONCERNS

Large gap between two front teeth.



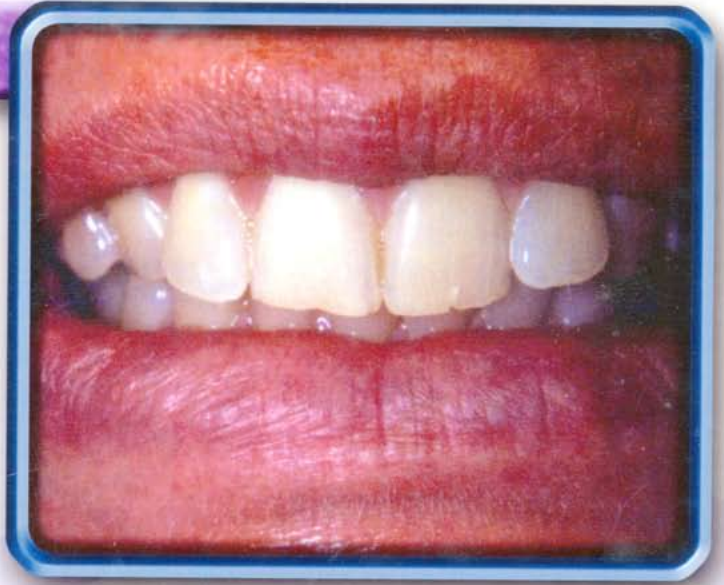## SOLUTION

In this case this gap was closed by treating just four teeth with ceramic restorations, many gap closures require a minimum of eight to ten teeth to close gaps. This picture was taken at placement two weeks after initial appointment.



## CONCERNS

Dark yellow teeth, worn teeth, teeth out of position. Notice forced smile lip positions.



## SOLUTION

Bright natural color obtained with proper ceramic selection, correct width, length correctly follows patients lower lip line. Notice how lips are filled out.

